

# Male or Female? Old or Young?

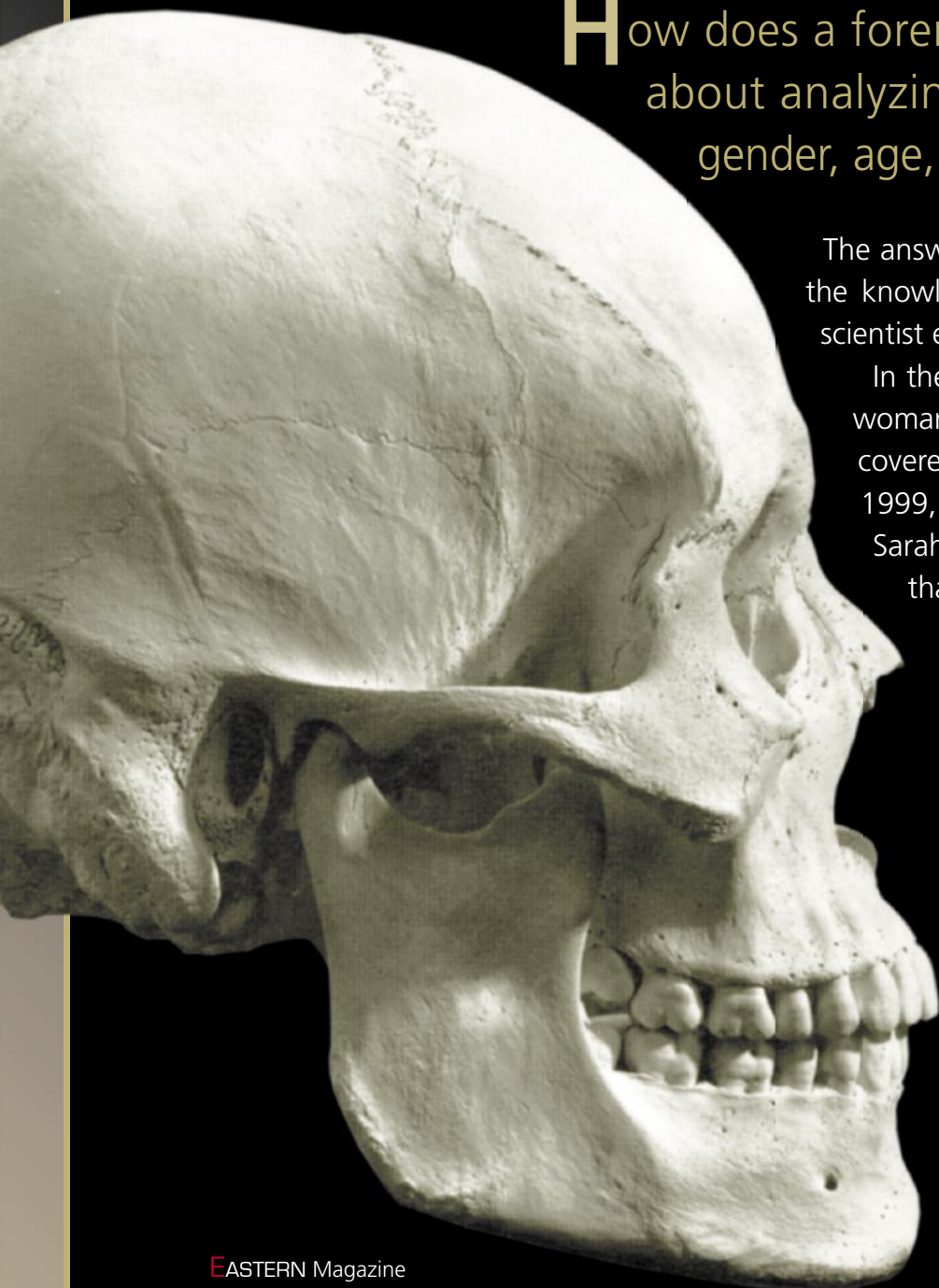
By Stefanie Pettit

How does a forensic anthropologist go about analyzing bones, determining gender, age, trauma and even race?

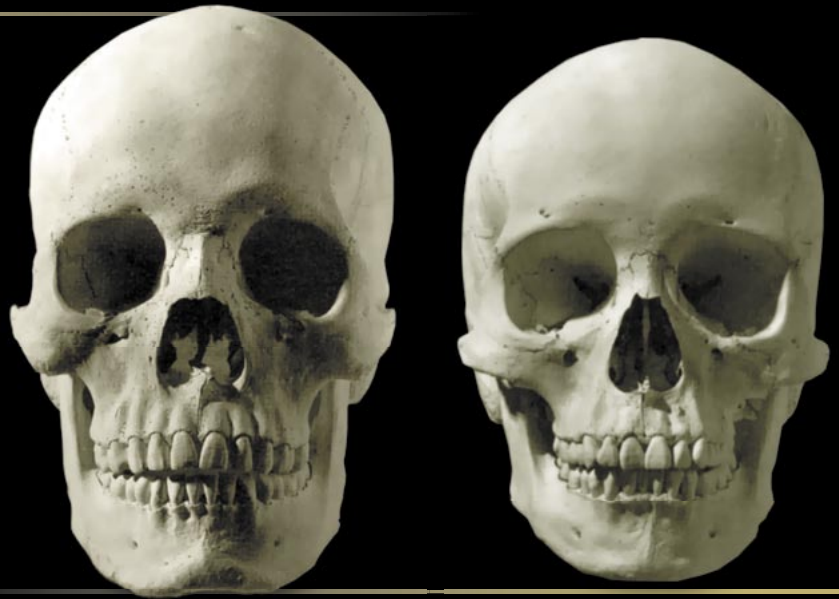The answer is in the bones themselves and the knowledge brought to the task by the scientist examining them.

In the case of Kelly Conway, the young woman whose skeletal remains were recovered from a furnace in Spokane in 1999, Eastern's forensic anthropologist, Sarah Keller, found some key pieces that yielded the answers – in the dimensions of the head of the femur bone, curvature of the collar bone, shape of the pubic bone, appearance of the bones in general (slender and slight rather than heavily muscled), etc.

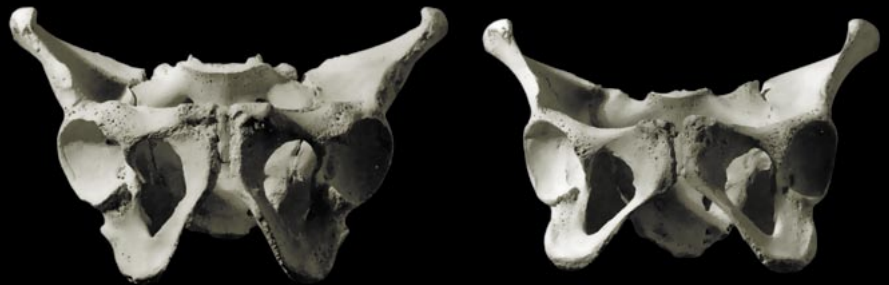
Here are some photos from *Human Osteology*,\* the textbook Keller uses in her physical anthropology class, and what a scientist can determine from the structures. (Bones from the pelvic region are often the most telling.)



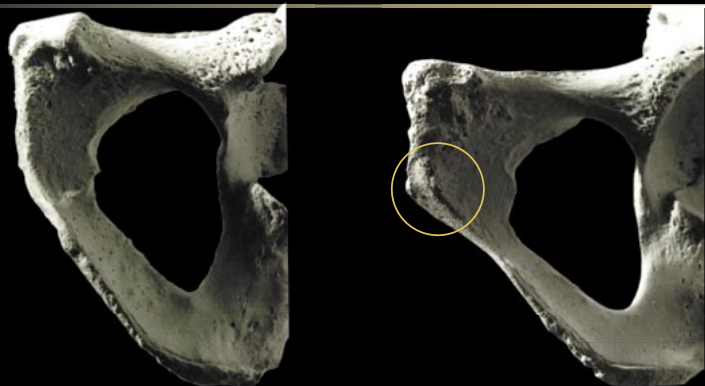
Front views of male and female adult skulls. Although there are cranial variations within each gender, these two skulls are reflective of the more extreme ranges of "male" and "female." Generally, the female skull is smaller and lighter in construction (more gracile); male features are more robust (squarer eye sockets and chins, larger and broader palates, etc.)



Male (left) and female (right) pelvis. The female pelvis has a more open appearance, whereas the male pelvis is more pinched toward the base.



The ventral arc of the female pubis (right) has a slightly elevated ridge of bone present, compared with the male (left).



Normal lumbar vertebra (left). Bony lipping and spur formation is present on the vertebra with degenerative arthritis (right).

